

Selective Ablation Of Surface Enamel Caries With A Pulsed Nd:YAG Dental Laser

David M. Harris, Ph.D, Joel M. White, DDS, Harold Goodis, DDS, Charles J. Arcoria, DDS, James Simon, DDS,
William M. Carpenter, DDS, Daniel Fried, PhD, John Burkart, PhD, Michael Yessik DDS, Terry Myers, DDS

(DMH, JMW, HG) Department of Preventive and Restorative Dental Sciences,
University of California,
San Francisco, CA 94143

(CJA) Baylor College of Dentistry,
Dallas, TX 75246-2098

(JS, WMC) University of the Pacific School of Dentistry,
San Francisco, CA 94115

(JB) University of Utah,
Salt Lake City, UT 84121

(MY) Incisive, LLC,
Richmond, CA 94806

(TM) The Institute for Advanced Dental Technologies,
Bloomfield, MI 48304

Address Correspondence:

David M Harris, PhD
Bio-Medical Consultants, Inc.
4256 Heyer Avenue
Castro Valley, CA 94546
TEL: (510) 583-7574
FAX: (305) 723-6275
Email: bmcinc@comcast.net

ABSTRACT:

Background and Objective: High intensity infrared light from the pulsed Nd:YAG dental laser is absorbed by carious enamel and not absorbed by healthy enamel. Consequently, this system has potential for selective removal of surface enamel caries. Safety and efficacy of the clinical procedure was evaluated in two sets of clinical trials at three dental schools. Selective ablation was evaluated with FTIR spectroscopy.

Study Design / Materials and Methods: Carious lesions were randomized to drill or laser treatment. Pulp diagnosis, enamel surface condition, preparations and restorations were evaluated by blinded evaluators. In Study I surface caries were removed from 104 third molars scheduled for extraction. One week post-treatment teeth were evaluated clinically, extracted and the pulp was examined histologically. In Study II 90 patients with 462 lesions on 374 teeth were randomized to laser or drill and followed for six months.

Results: Pulsed Nd:YAG laser removal of surface enamel caries was demonstrated to be both safe and effective. Caries were removed in all conditions. There were no adverse events and both clinical and histological evaluations of pulp vitality showed no abnormalities. A significantly greater number of preparations in the drill groups vs. laser groups entered dentin (drill = 11, laser = 1, $p = 0.007$).

Conclusion: The more conservative laser treatment removed the caries but not the sound enamel below the lesion. The pulsed Nd:YAG dental laser was found to be both safe and effective for surface caries removal.

Keywords: Enamel caries, pulsed Nd:YAG laser, histology, clinical trials, selective photothermolysis.

INTRODUCTION:

Dental caries is the destruction of the mineralized structure of the tooth, caused by bacterial action. The consequence of bacterial growth is proteolysis of the organic framework of the enamel by bacterial enzymes and acid decalcification of the enamel rods. A brown pigmentation appears in early lesions, the result of bacterial pigments associated with caries and the Maillard reaction between proteins and small aldehydes.¹

Our current minimally-invasive approach in restorative dentistry advocates that all carious tissue should be removed from enamel.²⁻⁴ To achieve this, a technique for the selective removal of dental caries that conserves healthy tissue is indicated. The dental laser presents a new method for caries treatment. Selective ablation of surface enamel caries with laser energy has a potential that is not possible with current alternatives such as the high-speed handpiece or air abrasion. Selective ablation of caries has been reported in extracted teeth with the argon fluoride laser,⁵ 2nd harmonic alexandrite,⁶ frequency tripled Nd:YAG,⁷ pulsed Er:YAG⁸ and clinically for the pulsed Nd:YAG,⁹⁻¹² although it is theorized that each wavelength achieves "selectivity" through different photophysical processes.

The very low absorption of healthy human enamel at the 1064 nm wavelength of the Nd:YAG results in high ablation thresholds. On the other hand, at this wavelength dental caries and its combustion by-products have greater absorption and consequently lower ablation thresholds than healthy enamel. This is an advantage for use of the pulsed Nd:YAG laser for caries removal since it provides a window of laser parameters that will remove carious enamel, leaving healthy enamel intact.⁷

Figure 1, a sample of an interproximal caries lesion irradiated ex-vivo, is provided to introduce the reader to the general concept of selective ablation of enamel caries. The left panel is the lesion before laser ablation. The middle panel shows the surface debris immediately after irradiation. The right panel shows the enamel surface that remains after irrigation, debridement and acid etching has removed the surface debris. Note that discolored sound enamel is revealed after removal of the lesion.


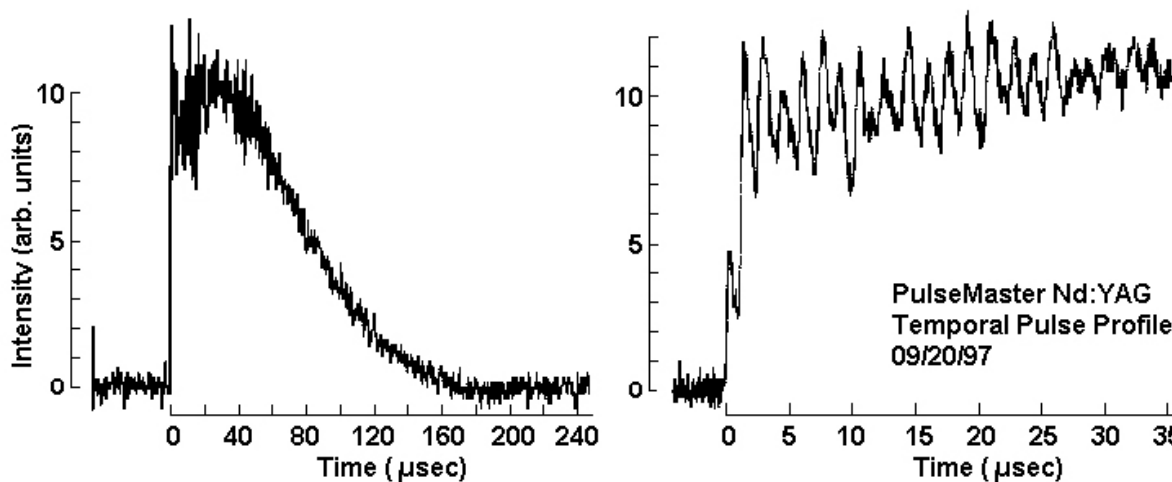


Figure 1.
Top: Dental caries.
Middle: Pulsed Nd:YAG ablation by-products (160 mJ, 10 Hz).
Bottom: Debris removed with acid etch and polishing. Enamel surface was faceted for reflection spectroscopy.

After initial experience with this procedure in dental practice^{9,10,13} and the laboratory¹⁴⁻¹⁸ we have conducted university-based clinical trials to evaluate the safety and efficacy of the pulsed Nd:YAG dental laser for surface enamel caries removal. This paper reports the results from two randomized, multicenter clinical trials sponsored by American Dental Technologies, Inc., (Corpus Christi, TX 78405) that were conducted under FDA regulations. In Study I, *in vivo* preparation of third molar caries was randomized to laser or high-speed handpiece. Preparation and restoration were followed by extraction at one week to evaluate pulp histology. In Study II, restored teeth were evaluated clinically at intervals from one week to six months. Both studies were conducted at Baylor College of Dentistry, The University of California at San Francisco, School of Dentistry (UCSF), and the University of the



Pacific School of Dentistry (UOP).

Figure 2. Temporal pulse structure of free-running pulsed Nd:YAG. Note the different time scales illustrating the 100 μ sec duration (FWHM) of the entire pulse (left) and about 1.0 μ sec duration micropulses (right).

MATERIALS AND METHODS:

Laser description

The PulseMaster™ Dental Laser System used for these studies is a free-running pulsed Nd:YAG laser with a full-width-half-maximum pulse duration of 100 μ sec. The energy output of the laser was monitored with a calibrated, Molecron ED-200 pyroelectric calorimeter. A Molecron P5 ultrafast pyroelectric with a rise time of 500 ps was used to resolve the micropulses (Figure 2).

The laser was capable of producing pulse energies from 30 to 320 mJ, and repetition rates from 10 to 100 Hz. Laser energy was delivered through a 300 μ m diameter silica fiber that was held in contact with the tissue. The PulseMaster(was originally designed and manufactured by Incisive Technologies, Inc. in San Carlos, CA, and in 1996 the technology (and clinical study) were transferred to American Dental Technologies, Inc.

Spectroscopy

Fourier Transform infrared (FTIR) spectroscopy was performed with a Laser Precision RXF-30 FTIR Microscope in the reflective mode. Specular reflectance FTIR spectroscopy requires a parallel-plano tissue surface so that light reflected from the sample surface can be directed to the detector. Due to this constraint, FTIR spectroscopy was performed on faceted samples of interproximal enamel caries that provided a flat surface parallel to the detector. Spectroscopy was performed before and after irradiation with the pulsed Nd:YAG.

Clinical trials protocol and histologic evaluation of extracted third molars (Study I).

Inclusion / exclusion criteria. Adult patients (≥ 18 yr.) requiring third molar extraction, having at least two teeth with pit and fissure caries located on occlusal, buccal or lingual surfaces above the enamel-cementum junction, were included in the study. The teeth were symptom free, fully developed and completely erupted. Non-carious, healthy,

normal appearing teeth were used as controls for pulp vitality determinations. Teeth were excluded from the study if there was visible, tactile or radiographic evidence of periapical pathosis, incompletely formed roots, previous restorations, evidence of periodontitis or pulpitis, or gross radiographic evidence of caries that had penetrated into dentin.

Pulp diagnosis. Pulp condition was evaluated before and after treatment and at one week post-treatment when teeth were scheduled for extraction. A blinded, independent clinician reviewed the data and provided a pulpal diagnosis based on thermal and electrical pulp testing and radiographic appearance.¹⁹ Blinded clinical review of the symptomatic, electrical, thermal and radiographic data provided an independent confirmation of the pulpal diagnoses. Teeth were diagnosed as being Healthy (H), with Reversible Pulpitis (R), or with Irreversible Pulpitis (I) (Table 2).

Prior to treatment the test teeth were isolated with cotton rolls, dried with sterile gauze and the pulp was tested. Thermal testing consisted of placement of an ice stick (0°C) on the facial surface of the tooth for five seconds. The patient was instructed to respond if the stimulus was painful. No response or a response that immediately disappeared when the ice stick was removed was considered normal. Vitality was confirmed with an electrical pulp tester probe (Automatic Pulp Tester, Analytic Technology, Redmond, CA) placed on the facial surface. A small, gradually increasing current was passed through the tooth. Patients released a handheld button when a sensation was felt and a digital display recorded the level where the patient responded (0-80). Since the teeth were asymptomatic with absence of caries (control) or caries limited to enamel, a response at any level ≤ 70 was considered normal.

Treatment groups. Prior to treatment patients were randomized to receive either laser or drill treatment. Anesthesia was not used during either treatment unless requested by the patient.

The laser was set to deliver 100 mJ pulses at a repetition rate of 20 Hz, yielding an average power of 2.0 Watts. The fiber tip was cleaved and power levels tested with a calibrated power meter (Molelectron PM600, Molelectron Detector, Inc., Portland, OR). Laser energy was delivered with the fiber in contact with the caries lesion and kept in constant motion. A flash and a “popping” noise accompanied ablation. The endpoint was reached when the operator determined that the caries were removed.

In the drill group the caries was removed with a 1/2 round carbide crosscut fissure (701) or pear-shaped (330) bur in a high-speed handpiece. The endpoint for cavity preparation with the drill was also when the operator determined that the caries were removed.

Clinical evaluations. After caries removal the treated surface was acid etched with orthophosphate acid. Prior to restoration teeth were evaluated for the following:

- 1) Caries removal: Incomplete or complete removal of 1st degree caries.
- 2) Preparation penetration into dentin.
- 3) Enamel condition: Presence of cracking and/or fissures, surface debris and discoloration were noted.
- 4) Preparation evaluation: Evaluation of the outline form, axial wall, cavosurface margin, retention, and overall preparation were rated according to the following scale:

E	=	Acceptable, within criteria
S	=	Acceptable, some deviation from criteria
U	=	Correctable, showing major criteria deviation
I	=	Not correctable
- 5) Acid Etch Evaluation: Evaluation of acid etch per manufacturer recommendations as follows:

E	=	Uniform frosty white
U	=	Patchy or incomplete frosty white - re-etch to correct.
I	=	Cannot achieve complete etch over surface of preparation

Preparations were restored with a hybrid resin (TPH, Dentsply Caulk, Wilmington, DE) and the restoration evaluated.

- 6) Restoration Evaluation - Surface, margin, retention, and whether the restoration is intact and serviceable at the follow-up using the above rating scale.

Histologic evaluation. After extraction, the apical 1/3 of each root was removed with a high speed handpiece with air/water coolant and the tooth placed in 10% formalin for fixation. Teeth were removed from formalin after three days and decalcified in 10% EDTA for two weeks, then placed in Easy Cut bone decalcification solution (American Master Tech Scientific, Inc., Lodi, CA) for an additional 7-14 days or until soft enough to section. Teeth were then dried and embedded in paraffin. Six-micrometer sections were taken through the pulp chambers and stained with hematoxylin and eosin.

Two evaluators, blinded to the treatment condition, examined the prepared slides under light microscopy and measured the minimum straight line distance between from the preparation to the dentopulpal junction as the remaining dentinal thickness (RDT).

The histological sections were reviewed while blinded to treatment (laser/drill) or control. The following criteria were used in the evaluations:

- 1) Aspiration of odontoblasts into the dentinal tubules
- 2) Increased vascularity (number of vessels)
- 3) Polymorphonuclear white blood cell infiltration from the vessels into the cell rich and cell free areas of the pulp
- 4) Microabscess formation opposite the area of treatment.
- 5) Superficial response limited to the odontoblastic or cell free zone.
- 6) Deep response extended to the cell rich zone and into the central portion of the pulp.
- 7) Necrosis by complete round cell infiltration and complete loss of any cellular detail.

Over-all each tooth was scored as Normal Pulp Tissue: YES or NO.

Clinical trials protocol (Study II).

The same criteria, design, techniques and investigators that were used in Study I were repeated in Study II. However, teeth were not extracted, consequently, histology was not evaluated, and all teeth with surface caries were eligible for inclusion. As before, sites were discrete and independent of any previous restoration. Clinical evaluations were made prior to treatment, immediately following treatment, and at one week, one month, three month, and six month post-treatment follow-ups.

Methods of analysis.

In Study I, the laser or the drill was randomized within patients who had at least two affected teeth. Study II randomized patients to treatments, with the same treatment applied to all teeth within a patient. To compare results from these two studies, the tooth or site was used as the unit of analysis.

In Study II, age was compared between treatments using a two way analysis of variance, with the factors, center and treatment. Randomization was stratified on gender and no differences were tested. The treatment site was used as the primary unit of analysis. In most cases the treatment site was the tooth, but occasionally there were two or more distinct sites on a tooth which were treated and evaluated separately. Significance was determined over the number of sites treated. For symptoms, thermal and electrical evaluations, and the pulp diagnosis, the tooth was used as the unit of analysis. Proportions of patients with the preparation extending into the dentin were compared using Mantel-Haenszel chi-square tests summed over studies.

Enamel condition, restoration surface, margin, retention, and intact / serviceable evaluations were tabulated and compared using Mantel-Haenszel summary chi-square tests.

Electrical threshold and thermal stimulus data were converted to a response or no response value for assessment by the evaluators for their determination of pulp vitality. Pulp vitality plus symptom assessment were used to arrive at a clinical pulp diagnosis.

RESULTS:

Demographics, sample size

Table 1 summarizes the demographics of the patients plus the number of teeth treated or evaluated by center and treatment type enrolled in both Study I and Study II. In Study I, 104 third molars in thirty-one patients at three study centers were evaluated. Forty-three teeth were treated with the laser, thirty were treated with the drill, and thirty-one teeth were evaluated as controls. In Study II, 374 teeth in ninety patients provided 88 control teeth, 186 teeth treated with the drill and 190 teeth treated with the laser. Since there were more than one discrete lesions on some teeth there were 207 drill treatment sites and 215 laser treatment sites.

STUDY I										
	Baylor			UCSF			UOP			TOTAL
Total Patients	10			14			7			31
Males	4			9			2			15
Females	6			5			5			16
Teeth	C	D	L	C	D	L	C	D	L	C D L
	7	8	18	17	14	14	7	8	11	31 30 43
STUDY II										
Total Patients	22			45			23			90
Males	6			19			11			36
Females	16			26			12			54
Sites	C	D	L	C	D	L	C	D	L	C D L
	22	48	69	43	69	87	23	90	59	88 247 215

Table 1. Demographic summary. Study I: Third molars extracted at 1 week; Study II: All teeth with caries evaluated at 1 week, 1 month, 3 months and 6 months. C = control, D = drill, L = laser.

Significant differences among centers in ages were noted in Study I, ranging from a mean of 25 years at UCSF to a mean of 28 years at Baylor and a mean of 31 years at UOP. At UCSF more females than males were studied, while at the other two centers, males were more predominant. In Study II no significant differences in ages or gender among centers or between treatment groups were noted. Overall 121 patients were studied, with 70 females and 51 males. The average age was 29 years with a range from 18 to 61 years.

Treatment summary

Median operator estimate of procedure time (including caries removal and inspection) was 1.0 minutes for the drill and 2.5 minutes for the laser treatment. None of the teeth treated required anesthesia.

In both Study I and Study II teeth were treated with 100 mJ pulses at a repetition rate of 10 Hz (1 Watt average power). In Study I the median number of pulses used for caries removal in enamel was 1477 pulses, with a range of 567 to 6399 pulses or 57-640 Joules per treatment site. In Study II the median number of pulses was 789 with a range from 30 to 3737. This represents 3 to 374 Joules of total energy. The maximum energy delivered to any single tooth was 640 Joules in Study I.

Follow up was completed on all patients at all times except for three patients in Study II. One patient missed the one week and one month evaluations, but was evaluated at three and six months. One patient missed the one week and three month evaluation, but was evaluated at one and six months. One other patient moved before the six month evaluation.

Histology results.

Average remaining dentin thickness for all teeth was 2.4 mm within a range of 1.0 to 5.0 mm. The histological sections revealed mild increased vascularity in three laser treated teeth, one drill treated tooth and one control tooth. Neither treatment caused a significant change in the architecture and morphology of the pulp. All other teeth were rated 0 (normal pulp). Differences among groups were not significant.

Clinical results.

Pulp vitality, enamel condition, preparation and restoration evaluations from Study I and Study II were combined for analysis up to 1 week post-treatment. In all, 535 carious lesions in 121 patients were included. The laser was used on 258 sites, the drill was used on 236 sites and 31 teeth were evaluated as controls.

Safety - pulp diagnosis (Table 3). All treated teeth remained asymptomatic through the evaluation period of Study I. Only one event was reported, consisting of sensitivity to the laser. It started at the beginning of laser treatment and lasted 30 seconds. This was recorded by the operator as related to general anxiety of the patient but not related to the treatment.

PULP DIAGNOSIS										
		STUDY I extracted			STUDY II 6 Mo. FU			STUDY I and II COMBINED		
		C	D	L	C	D	L	C	D	L
Baylor	H	7	8	18	22	48	69	29	56	87
	R	0	0	0	0	0	0	0	0	0
	I	0	0	0	0	0	0	0	0	0
UCSF	H	17	13	14	43	49	61	60	62	75
	R	0	1	0	0	1	0	0	2	0
	I	0	0	0	0	0	0	0	0	0
UOP	H	7	8	11	23	86	57	30	94	68
	R	0	0	0	0	0	0	0	0	0
	I	0	0	0	0	0	0	0	0	0
Total	H	31	29	43	88	183	187	119	212	230
	R	0	1	0	0	1	0	0	2	0
	I	0	0	0	0	0	0	0	0	0

Table 2. Pulp diagnosis evaluations by performance site and Group: C=Control, D=Drill, L=Laser.
Pulp diagnosis: H=Healthy, R=Reversible pulpitis, I=Irreversible pulpitis.

In Study II, three drill-treated teeth became symptomatic (two to biting and one to cold) at one week post-treatment. One laser-treated tooth became symptomatic to biting at one week. At subsequent appointments the teeth had become asymptomatic.

All pulp evaluations for the controls and laser treated teeth were healthy. At one week, one drill treated tooth in each study was diagnosed with reversible pulpitis. The Study I tooth had normal histology following extraction and the Study II tooth was healthy at later evaluations. All pulp diagnoses at 6 month were healthy. There were no statistically significant differences found among control, drill and laser teeth for pulpal diagnosis, symptom assessment, thermal assessment, or electrical vitality over the course of the six-month follow-up.

Efficacy - caries removed / preparation into dentin. Enamel caries was removed completely for all laser and drill-treated teeth. In Study I the preparation penetrated into dentin in one tooth in the Drill Group and none in the Laser Group. In Study II there were ten drill-treated teeth and in only one laser-treated tooth where the preparation penetrated into the dentin. Results summed over both studies demonstrated a significant difference between laser and drill groups ($p = 0.007$).

ENAMEL EVALUATION								
		STUDY I		STUDY II		COMBINED		DRILL vs. LASER
N=		DRILL	LASER	DRILL	LASER	DRILL	LASER	
CRACKED		1	0	0	0	1	0	$p = 1.000$
DEBRIS		0	4	0	50	0	54	$p \leq 0.001$
DISCOLOR		10	23	2	45	12	68	$p \leq 0.001$

Table 3: Post-treatment enamel evaluation. Significantly more debris and discoloration were observed in the LASER Group preparations relative to the DRILL Group preparations.

Post-treatment enamel evaluation. Table 3 presents a summary of the immediate post treatment enamel evaluation. One drill-treated tooth in Study I had cracking. In Study II, one laser-treated tooth was initially reported to have cracking, but on further examination it was determined that the appearance was due to debris in the fissure. There

was obviously no difference between laser vs. drill. Significant differences between laser and drill groups were obtained for remaining surface debris ($p < 0.001$) and discoloration ($p < 0.001$), which were much more prevalent in the laser group. The surface debris was removed by acid etch and any remaining discoloration was covered by the restoration.

Post-treatment preparation and restoration evaluation. The post treatment preparation evaluations were acceptable. However, in Study II at one center eight teeth in the first three patients randomized to the laser treatment lost the restorations at one week follow-ups. Procedural problems with the restorative material were identified as the cause. One laser treated patient (3 sites) at another center also lost restorations. This patient had poor dental hygiene and oral habits.

DISCUSSION:

Safety

Results from the evaluation of safety from these clinical trials were unremarkable. There were no abnormal histological changes and no loss of pulp vitality in either the laser or the drill groups. There were no adverse events reported. Thus, there were no unusual safety considerations and it is unlikely that the pulps suffered thermal damage as a result of laser treatment.

The safety of the laser procedure is consistent with previous reports. White, Goodis, and Daniels¹⁴ studied the pulpal response, evaluated histologically, to pulsed Nd:YAG laser exposures on freshly extracted human third molars. Care was taken to ensure that specimens retained vital pulp tissues. Even with 100 mJ pulses at 10 Hz for 2 minutes (120 J total exposure, maximum used in the study) there was no observed pulpal disruption. Maximum exposure in the present study was 640 Joules, also without pulpal disruption.

A side effect of both the laser and the dental drill is the production of heat that is conducted through enamel and dentin, potentially causing damage to the dental pulp. In fact, earlier studies using continuous wave Nd:YAG lasers reported pulp damage.²⁰ However, with pulsed laser energy, like the 100 μ sec duration pulses used in this study, the target tissue is ablated before heat has time to be conducted to the pulp tissue. If the repetition rate is low (10-20 Hz), then the tissue has time to cool down between pulses. Therefore, pulsing the laser beam can aid in avoiding thermal damage to the pulp.¹⁵

It should be noted that one drill treated tooth was diagnosed with a reversible pulpitis following pulp vitality testing, although a review of the patient's records indicated that the tooth was asymptomatic. When the histology was evaluated none of the teeth at that center were judged to be inflamed.

Efficacy

There were no unusual efficacy considerations. Surface caries were completely removed with both laser and drill techniques in all instances. However, restoration evaluations revealed that special consideration should be given to materials used for laser restorations since the defect will typically be smaller than with standard techniques and will not provide the same mechanical retention as from undercuts and dovetails such as used for large amalgam restorations. For this study the preparation was complete when the caries were removed, analogous to the preparation achieved with the new air abrasion systems.⁴ This approach to minimally invasive dentistry replaces the old concept of "extension for prevention" with "conservation of healthy tooth structure" which is accomplished with bonding restorations such as flowable composites and preventive resin restorations.⁴

In the drill group the preparation extended into the dentin in eleven teeth, whereas, in only one laser treated tooth did the preparation penetrate into the dentin, and treatment was completed using the drill. We interpret this to mean that the drill is more aggressive and will remove healthy tissue below the lesion, increasing the probability of entering dentin. On the other hand, the laser represents the more conserving technique because it selectively removes the diseased tissue and does not remove healthy enamel.

In these trials the lesions were carefully selected according to the inclusion criteria. Consequently, none of the finished laser preparations had unsupported enamel. However, in clinical practice occasions may arise where unsupported enamel remains after caries removal, necessitating modification of the preparation with the high speed handpiece.

Spectroscopy

In this clinical study there was a high incidence of post-treatment enamel discoloration in the Laser Group. Yet evaluators recorded that all caries had been removed. To evaluate this paradox and gain insight into the mechanism of action we measured the chemical composition of the lesions spectroscopically.²¹ Five samples with superficial enamel caries were faceted and evaluated with a Fourier transform infrared red spectroscope before and after irradiation with the pulsed Nd:YAG laser at 100 mJ, 20 Hz. Figure 3 shows representative spectra collected from the sample illustrated in Figure 1. The presence of water is indicated by the signal below 6 μm , protein (amide bands, carbonate) if present shows absorption in the 6-8 μm band, and phosphate in the 9-10 μm band. The spectra of healthy adjacent enamel show a lack of absorption in the range 6-9 μm . However, the absorption spectra of carious enamel show a strong organic component

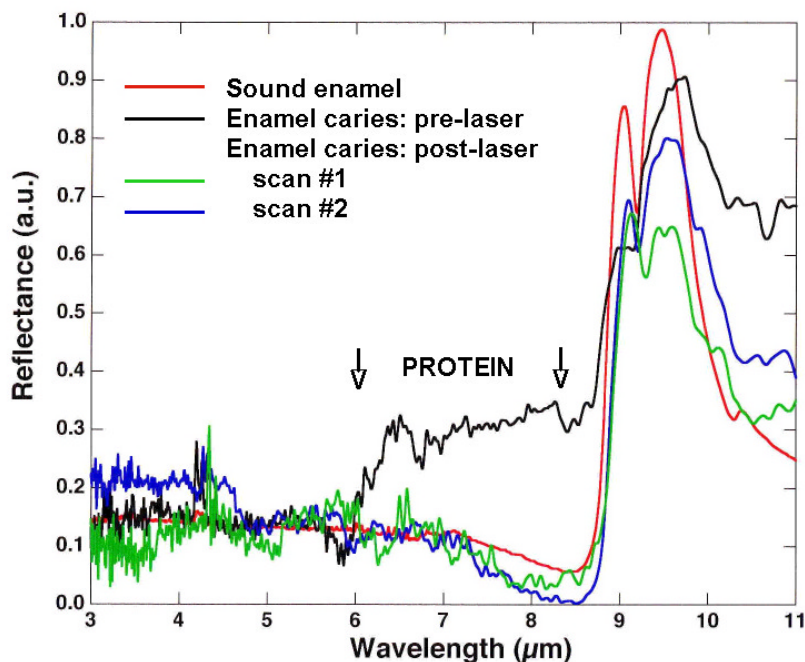


Figure 3. Fourier Transform Infrared Spectroscopy of enamel caries showing protein component prior to ablation that disappears after Nd:YAG irradiation. The spectrum of sound enamel is shown for comparison.

presumably associated with the presence of bacteria and protein debris. Following irradiation the protein component at the lesion site is absent and, although the surface is still stained, the spectra resemble that of sound enamel.

The discoloration reported probably relates to this layer of stained enamel below the lesion that was not removed by the laser (Figure 1). Yet, in the drill group there was significantly less discoloration reported. This is because the visual endpoint for the drill is removal of discolored tissue even if it is sound enamel.

Mechanism of action

We have used the measurement of the photoacoustic response to Nd:YAG ablation of carbon (graphite), and both diseased and sound dentin and enamel to determine the relative absorption of carious and noncarious dental hard tissue. Simply put, the photoacoustic response is the “pop” made when a pulse laser beam ablates a target material. The loudness of the photoacoustic response is proportional to the amount of ablation.²¹ In addition, the photoacoustic response is a sensitive method for detecting the respective ablation thresholds for various tissues.^{22, 23} The acoustic signal, created by the explosive release of gases and plume ejecta, increases by orders of magnitude when fluence increases above ablation threshold.

There is a very small acoustic signal accompanying the irradiation of healthy enamel since enamel absorbs poorly at 1064 nm. In fact, the incident fluence needed for ablation of sound enamel can not be achieved with a six Watt, 100 μsec , pulsed Nd:YAG Dental Laser System through a 300 μm fiber. However, if the tissue is pigmented, as with caries, then there is a strong acoustic signal as the pigmented tissue is ablated away. Photoacoustic measurements and spectroscopy both support the assumption that the Nd:YAG laser is absorbed by and ablates pigmented tissue.¹⁹ Carbonized organic combustion byproducts (char) also absorb strongly and are ablated at 1064 nm, thus, completing the removal of the organic component. In the case of carious enamel, ablation will cease once the organic material is removed and the laser pulses encounter sound enamel. The auditory endpoint is useful clinically, the practitioner knows the target is ablated when he can no longer elicit a photoacoustic response. Therefore, pulsed Nd:YAG laser ablation of enamel caries is both selective and self-limiting.

In summary, The PulseMaster™ Nd:YAG laser was safe and effective in removing first degree dental caries, was comparable in safety and efficacy to a high speed dental handpiece, and showed no adverse events or safety problems. Use of the drill may result in more inadvertent penetration into the dentin.

ACKNOWLEDGMENTS:

These studies were funded by Incisive Technologies, Inc. San Carlos CA and American Dental Technologies, Inc., Corpus Christi, TX and NIDCR DE12091 (DF). We thank John Sulewski, Bunny Arcoria, Kim Tran, and Dorothy Volk for their assistance.

REFERENCES:

1. GA Kleter. Discoloration of dental carious lesions (a review). *Arch Oral Biol* 1998 Aug;43(8):629-32
2. H Hosoda, Fusayama T. A tooth substance saving restorative technique. *Int Dent J* 1984;34(1):1-12.
3. RJ Simonsen. Conservation of tooth structure in restorative dentistry. *Quintessence Int* 1985; 16(1):15-24.
4. JM White, WS Eakle. Rationale and treatment approach in minimally invasive dentistry. *JADA* 2000;131:13-19S.
5. MK Arima, K Matsumoto Effects of ARF:Excimer laser irradiation on human enamel and dentin. *Laser Surg Med* 1993; 13:97- 105.
6. P Rechmann, T Hennig, von den Hoff, R Kaufmann. Caries selective ablation using a 2nd harmonic alexandrite laser. ISLD 3rd Int'l Congress, 1992.
7. T Hennig, P Rechmann, C Pilgrim, H-J Schwartzmaier, R Kaufmann. Caries selective ablation by pulsed lasers. *Proceedings SPIE* 1991; 1424:99-105.
8. R Hibst and U Keller. Experimental studies of the application of the Er:YAG laser on dental hard substances: Measurement of the ablation rate. *Laser Surg Med* 1989; 9:335-344.
9. TD Myers and WD Myers. In Vivo caries removal utilizing the YAG laser. *J Mich Dent Assoc* 1985; 67:66-69.
10. TD Myers and WD Myers. The use of a laser for debridement of incipient caries. *J Prost Dent* 1985; 53:776-779.
11. K Matsumoto, T Nakayama. A morphological study on the enamel and dentin irradiated by pulsed Nd:YAG laser (D-Lase 300). ISLD Proceedings Third Int'l Congress on Lasers in Dentistry, Salt Lake City, UT 1992:135-136.
12. KHP Lee, WS Chao, KT Tran, TD Myers, JM White. Caries removal and restoration using Nd:YAG laser and air abrasion. *J Dent Res* 1996; 75:91.
13. JE White, HE Goodis, JC Setcos, WS Eakle, BE Hulscher, CL Rose. Effects of pulsed Nd:YAG laser energy on human teeth: A three year follow up study. *J Amer Dent Assoc* 1993; 124:45-51.
14. JE White, HE Goodis and TE Daniels. Effects of Nd:YAG laser on pulps of extracted teeth. *Lasers in Life Sci* 1991; 4:191- 200.
15. JE White, MC Fagan, HE Goodis. Intrapulpal temperatures during pulsed Nd:YAG laser treatment of dentin, in vitro. *J Periodontol* 1994; 65(3):255-259.
16. DM Harris. Contact pulsed Nd:YAG laser ablation of human dentin: ablation rates and tissue effects. *Proc SPIE* 2128 1994; :409-415.
17. DM Harris. Contact pulsed Nd:YAG laser ablation of human dentin: fiber tip and crater morphology (SEM). *Proc SPIE* 1994; 2128:416-423.
18. CJ Arcoria, M Dusek, B Vitasek-Arcotia (1994). Pulpal effects of a high rep rate Nd:YAG laser. *J Clin Laser* (need ref)
19. S Seltzer and IB Bender. Differential Diagnosis. Chapt 18 in *The Dental Pulp*, 2nd Ed. JB Lippincott Co., Philadelphia 1975:324-346.
20. Y Launay, Mordon S, Cornil A, Brunetaud JM, Moschetto Y. Thermal effects of lasers on dental tissues. *Lasers Surg Med* 1987; 7:473-477.
21. DM Harris and D Fried. Pulsed Nd:YAG laser selective ablation of surface enamel caries: I. Photoacoustic response and FTIR spectroscopy. *Proceedings SPIE* 2000; 3910:164-170.
22. CKN Patel and AC Tam. Applications of photoacoustic sensing techniques, *Rev. Modern Phys.*, Vol. 58(2) 1986:381-431.
23. PE Dyer and RK Al-Dhahir, Transient photoacoustic studies of laser tissue ablation, *Laser-Tissue Interaction*, *Proceedings SPIE* 1990; 1202:46-60.