

HEARES 01456

Postnatal growth of cochlear spiral in mongolian gerbil *

David M. Harris, Robert Rotche and Thomas Freedom

Department of Otolaryngology-HNS, University of Illinois College of Medicine at Chicago, Illinois, U.S.A.

(Received 2 April 1987; accepted 16 May 1990)

Measurements were made of cochlear dimensions in an age-graded series of Mongolian gerbils. The radii of the cochlear spiral at five locations and the length of the modiolus were determined from in situ photographs of mid-modiolar sections. The anterior to posterior dimensions of the auditory bulla and of the inferior colliculus were also measured to provide a general context for inner ear growth functions. At birth in this species, the cochlear capsule is still growing, and, although the basal turn is closer to the final adult proportion than more apical turns, all radii approach adult dimensions together at 9–10 days after birth (DAB). Comparison of the morphological development of gerbil otic capsule with the change in cochlear tonotopic mapping observed during physiological development shows that growth is complete before the onset of measurable electrical responses at 12–14 DAB.

Auditory growth and development; Gerbil; Cochlea; Otic capsule; Middle ear; Inferior colliculus

Introduction

Rubel's hypothesis of a changing frequency map during auditory development directed attention at the spatial distribution of frequency selectivity in the developing cochlea (Rubel et al., 1976; Rubel, 1978). Various techniques including damage patterns from overstimulation (Rubel and Ryals, 1983; Cousillas and Rebillard, 1985) direct recordings of cochlear responses (Harris and Dallos, 1984; Yancey and Dallos, 1985; Arjmand et al., 1988; Echteler et al., 1989) and mapping of central nervous system projections (Lippe, 1987; Lippe and Rubel, 1983, 1985; Ryan and Woolf, 1988; Sanes et al., 1989) now point to the existence of a period of tonotopic development.

The anatomic substrate of these functional changes is unclear. Thus, it has become necessary to evaluate the relative contribution of changes in

cochlear dimensions to these reported developmental changes in cochlear function. It is possible that in the mammalian ear functional changes may be related to the overlapping of continued otic capsule growth with this period of functional development as was noted in the avian ear (Ryals et al., 1984).

The development of the auditory system has been studied in numerous vertebrate species. However, timetables of development vary across species making comparisons difficult. Several investigators have adopted *Meriones unguiculatus*, the common Mongolian gerbil, as an experimental model (e.g., Schmeidt, 1989; Gans, 1989). In this species early stages of development are easily available for observation and experimental manipulation since gerbil pups are born with a very immature auditory system that develops rapidly until the onset of function at 10–12 DAB (Finck et al., 1972). In many ways the animal's hearing is adult-like by 1 month and shows signs of aging by 24–36 months (Schmeidt et al., 1987; Ostapoff and Morest, 1989; Keithley et al., 1989).

Measurements were made in a series of age-graded gerbils to provide detailed time tables for the growth of the otic capsule, basilar membrane,

* Data contained in this paper has previously been presented in abstract form; see Harris et al., 1986.

Correspondence to: David M. Harris, Ph.D. Wenske Laser Center, Ravenswood Hospital Medical Center, Chicago, IL 60640, U.S.A.

auditory bulla and inferior colliculus for comparison with the functional development of cochlear responses.

Methods

A breeding colony of adult Mongolian gerbils was monitored twice daily at 0800 and 1600 hrs for newborns. Animals born during the day (8-h resolution) were used for measurements up to 25 days and those born at night were used at 26 days and thereafter. All litters were culled to six or less siblings at birth.

Animals were perfused through the heart under heavy anesthesia with normal saline plus 0.5% methylene blue, a vital stain for nuclear chromatin. This was followed by neutral buffered 10% formalin also containing methylene blue. Heads remained in formalin for at least 48 h and were then decalcified in 1.0% nitric acid until radio-lucent. The entire head was then frozen sectioned with a sliding microtome which was placed on a photographic copy stand. A 35 mm camera with bellows, 55 mm macrolens, 250 frame film magazine, and motor drive was focused on the cutting plane from above. Following each slice, a photograph was taken of the cut surface. Reiteration produced a 35 mm film strip of serial sections through the entire specimen. For the data reported here, photographs were taken at 50 μm intervals.

Measurements of the inferior colliculus, auditory bulla and cochlea were taken directly from the film strip using a Vanguard Film Projector and a Numonics 1224 Digitizer. Each film strip begins with an image of a 1 cm^2 microscope reticule used to calibrate magnification. The magnification was entered into the digitizer so that measurements were scaled to their actual values. The dimensions represented on the film are quite accurate since the tissue had been only fixed and decalcified and was still in situ, eliminating the distortion and shrinkage caused by manipulating and dehydrating thin sections.

Linear measurements of auditory structures were taken according to the following criteria (Fig. 1). Modiolar axial length was measured at the midmodiolar section as the distance from the middle of the genu of the acoustic nerve to the cochlear apex. Radii of the cochlear spiral were measured

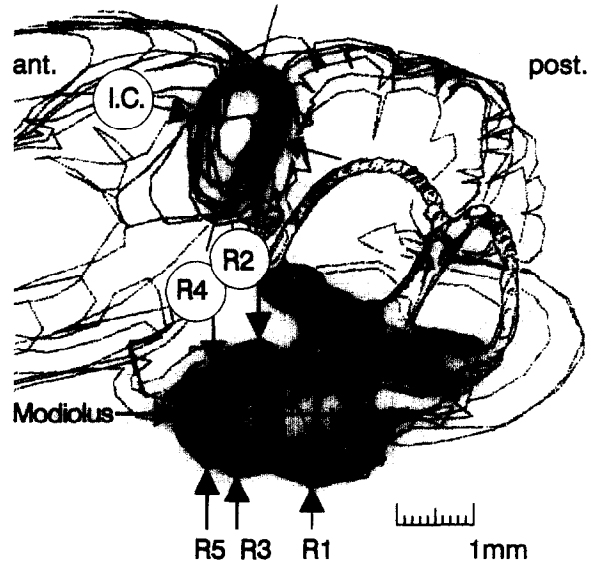


Fig. 1. Reconstruction of adult gerbil membranous labyrinth and central nervous system. Indicated are the measurements of inferior colliculus antero-posterior width (I.C.), length of modiolus, and radii of the cochlear spiral (R1–R5).

from the center of the modiolus to the most distant internal surface of the otic capsule. Measurements were made in the midmodiolar sagittal plane ventrally in the midbasal (R1), second (R3) and third (R5) turns and dorsally in the lower second (R2) and lower third (R4) turns. The entire film strip was examined to find the maximum anterior to posterior dimensions of the auditory bulla and of the inferior colliculus.

Inferior colliculus

The greatest anterior to posterior dimension of the inferior colliculus was measured from a series of 43 age-graded gerbils (Fig. 2b). In 35 animals both right and left colliculi were measured. In the remainder only the right colliculus was measured (total $N = 78$). The A-P dimension of the IC in 1 DAB gerbils median = 0.52 mm; range = 0.47–0.60 mm) is 46% of the adult dimension (Median = 1.22 mm; range = 1.14–1.28 mm). Growth of this structure continues at a decreasing rate to asymptote at > 30 DAB.

Middle ear

The middle ear cavity, contained within the auditory bulla, has a greatest dimension in the

sagittal plane, approximately parallel to the modiolar axis and close to the midmodiolar plane. At birth the bulla closely encapsulates the cochlear capsule. Beginning at 2–3 DAB cavitation of the middle ear spaces accompanies a rapid increase in

this anterior-posterior dimension up to about 60 DAB when it reaches adult proportions. The change in this dimension is shown in the data from 113 ears plotted in Fig. 2a. At 1 DAB the anterior to posterior length of the bulla is 2.7 mm, 32% of the 90 DAB length (8.5 mm). Up to 10–11 DAB the middle ear spaces are filled with fluid. By 13–14 DAB the gerbil has a dry and aerated middle ear.

Cochlear capsule

The growth of the cochlear capsule was measured from mid-modiolar sections of 115 age-graded cochleas. Midmodiolar axial length and the radii of the spiral, measured at 5 locations from midbase to apex, all grow at a decreasing rate. At 1 DAB the modiolus is between 1.32–1.75 mm in length (median = 1.475 mm). This represents 67% of the adult length (2.20 mm) which is reached by 8–10 DAB (Fig. 2c). At birth the radii of the basal turn (R1 and R2) are closer to the adult dimensions than the radii of more apical turns (Fig. 2d). From these data it can be generalized that the growth of the upper turns contribute more to modiolar elongation than growth of the basal turn. That is to say, during the period from 1–10 DAB the apical turns are growing more rapidly although all radii measurements asymptote at the same time. The morphological growth of the gerbil cochlear capsule appears to be complete by 10 DAB.

Body weight

Within the first 24 h after birth, 34 gerbils weighed between 2.4–3.6 g (median 3.0 g). Body

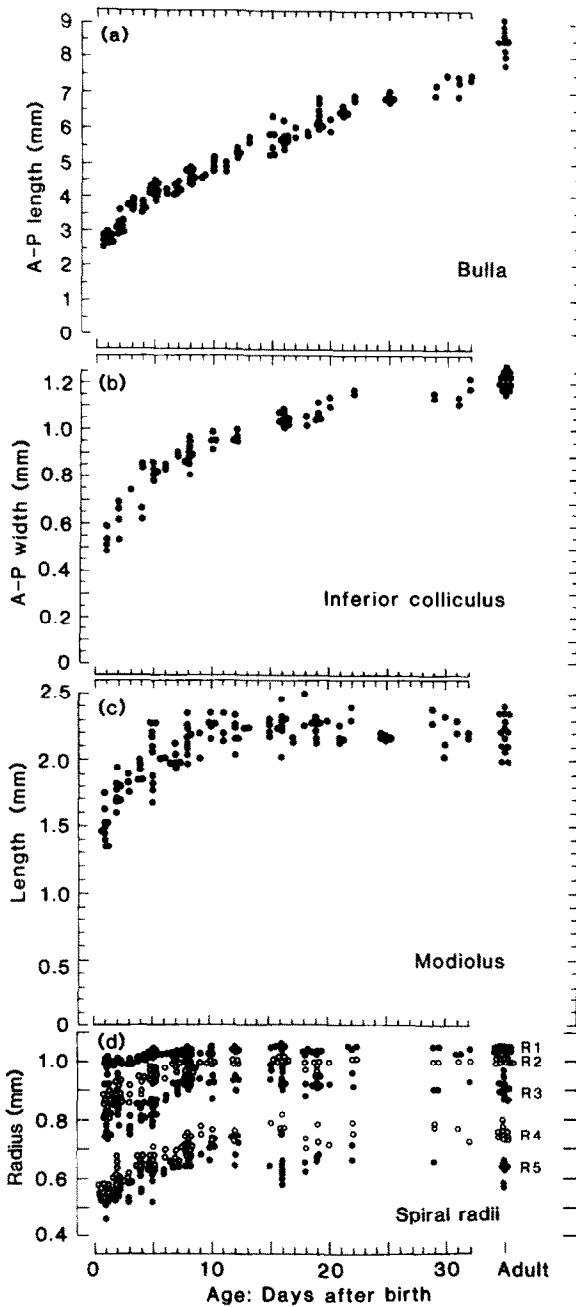


Fig. 2. Measurements of linear dimensions of gerbil middle ear (bulla) inner ear (Modiolus, spiral radii) and central pathway (inferior colliculus) during the first month post partum. The far right data points represent measurements from adults (90 days after birth [DAB] or greater). All measurements were made from sections in the sagittal plane. (a) Greatest anterior to posterior dimension of the auditory bulla. (b) Greatest anterior to posterior width of the inferior colliculus. (c) Modiolar length measured from the genu of the auditory nerve to the apical tip of the cochlear capsule. (d) Measurements of cochlear radii at 5 locations from mid-modiolar sections. R1: Mid-base; R2: upper basal turn, R3: second turn; R4: upper second turn; R5: third turn.

weight increases almost linearly to a median of 15.2 g (range: 12.2–18.8 g) at 20 DAB (Fig. 2). By this age they are eating solid food and body weight increases more rapidly up to 45.0 g (range: 39.8–48.0 g) at 45 DAB. Body weight continues to increase but at a slower rate past 90 DAB (median: 59.8 g, range: 49.5–72.3 g) well into adulthood. For a sample of 47 mature gerbils weighing between 55–96 g, the average weight for 19 males was 80.4 g and for 28 females was 69.5 g.

Discussion

The data plotted in Fig. 2 have been normalized to percent of the adult (90 DAB) dimension (Fig. 3). This provides a basis for comparison of modiolus length, bulla size, inferior colliculus width and body weight. Body weight increases for a long time into a gerbil's life.

Pneumatization of the middle ear spaces and dissolution of the meatal plug was observed to begin around 9–10 DAB and the air conduction pathway was patent at 12–13 DAB. This correlates well with the observations of Woolf and Ryan (1988). However, as shown in Fig. 3 the bulla continues to grow up to 60 days.

Comparison of modiolus elongation with radial expansion shows a basal to apical trend in morphological growth. During the prenatal period of development, the membranous labyrinth begins as a budding of the anterior portion of the vestibule. Growth begins at the base and progressive turns

are added as the cochlea spiral develops (Anson and Donaldson, 1973). Thus, the basal turn begins its growth earlier than the apical turns. Our measurements of the radii of each turn indicate that at birth the basal turn is more fully developed than the apical turn. However, it does not appear that the basal turn reaches adult proportions before the apical turns. Rather it is the case that all portions of the cochlea synchronously cease growing by 10 DAB.

The data shown in Fig. 2 suggest that the length of the modiolus can be used as an indicator of gross cochlear dimensions. We also assume that radii growth functions are proportional to the growth function of basilar membrane length. The morphologic growth of gerbil modiolus is shown compared with the low to high best frequency shift observed in mid-basal turn cochlear microphonics (Fig. 4). This comparison clearly shows that the cessation of growth of the cochlea occurs before acoustic stimulation first evokes cochlear responses on 12 DAB (Harris and Dallos, 1984). It has also been reported that direct driving of the stapes evokes responses as early as 10 DAB (Woolf and Ryan, 1988). Thus, in the gerbil the cessation of basilar membrane growth immediately precedes the onset of function. It is therefore unlikely that the age-dependent change in best frequency (Harris and Dallos, 1984; Yancy and Dallos, 1985; Echteler et al., 1989), frequency selectivity (Romand, 1987) or sensitivity (Finck et al., 1972; Woolf et al., 1986; Echteler et al., 1989) are due to

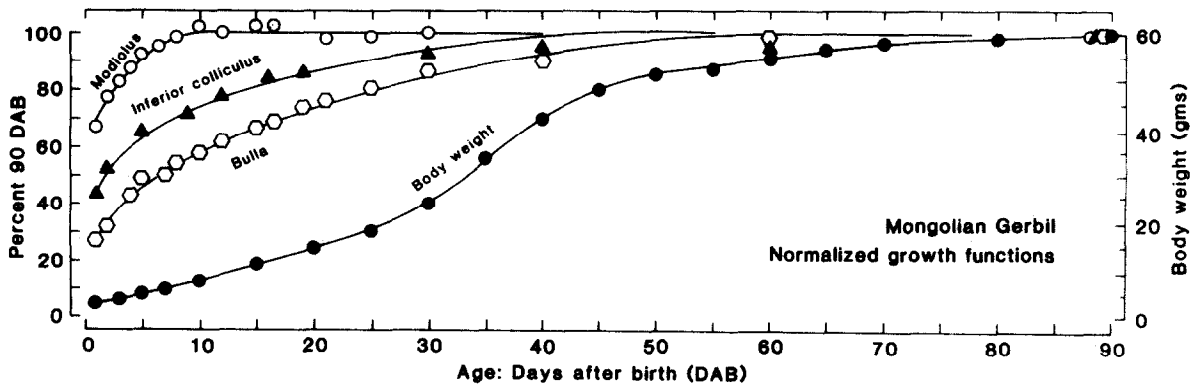


Fig. 3. Growth functions for gerbil middle ear cavity (bulla), inferior colliculus, and cochlear capsule (modiolus length). Data points represent medians of the raw data shown in Fig. 1 (a)–(c) converted to percent of the adult dimension. Mean body weight, shown for comparison, continues to increase past 90 DAB.

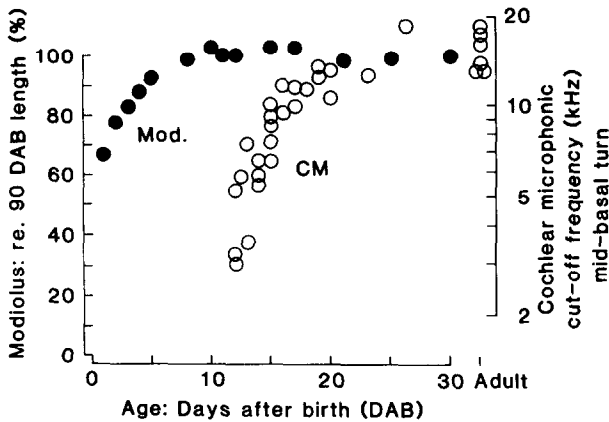


Fig. 4. The cochlear microphonic recorded at a constant location in the mid-basal turn undergoes a progressive change in tuning (cut-off frequency) from onset of function (11–12 DAB to at least 25 DAB (○, from Harris and Dallos, 1984). The growth of the cochlear spiral, inferred from the growth function for modiolus length (●), is apparently complete by 10 DAB. This comparison indicates that the shift in frequency mapping, observed during gerbil development, occurs after the cochlea has attained adult proportions.

either a progressive change in recording site location or a continued increase in basilar membrane dimensions influencing cochlear partition mechanics.

Acknowledgements

The authors thank Erica Harris for collection of the gerbil weight data and Glenn Krol, Chet Childs and Cindy Smith for technical assistance. This investigation was supported by funds provided by the Deafness Research Foundation.

References

Anson, B.J. and Donaldson, J.A. (1973) *Surgical Anatomy of the Temporal Bone and Ear*. W.B. Saunders, Philadelphia.

Arjmand, E., Harris, D. and Dallos, P. (1988) Developmental changes in frequency mapping of the gerbil cochlea: comparison of two cochlear locations. *Hear. Res.* 32, 93–96.

Cotanche, D.A., Saunders, J.C. and Tilney, L.G. (1987) Hair cell damage produced by acoustic trauma in the chick cochlea. *Hear. Res.* 25, 267–286.

Cousillas, H. and Rebillard, G. (1985) Age-dependent effects of a pure tone trauma in the chick basilar papilla: evidence for a development of the tonotopic organization. *Hear. Res.* 19, 217–226.

Echteler, S.M., Arjmand, E. and Dallos, P. (1989) Developmental alterations in the frequency map of the mammalian cochlea. *Nature* 341, 147–149.

Finck, A., Schneck, C.D. and Hartman, A.F. (1972) Development of cochlear function in the neonate mongolian gerbil (*Meriones unguiculatis*). *J. Comp. Physiol. Psychol.* 78, 375–380.

Gans, G. (1989) An automated approach for conditioning and testing the hearing of gerbils. *Brain Res. Bull.* 22, 475–80.

Harris, D.M. and Dallos, P. (1984) Ontogenetic changes in frequency mapping of a mammalian ear. *Science* 225, 741–743.

Harris, D.M., Rotche, R. and Freedom, T. (1986) Growth patterns of gerbil auditory system. *Abstr. Assoc. Res. Otolaryngol.* 9, 88.

Keithley, E.M., Ryan, A.F. and Woolf, N.K. (1989) Spiral ganglion cell density in young and old gerbils. *Hear. Res.* 38, 125–33.

Kraus, H.-J. and Aulback-Kraus (1981) Morphological changes in the cochlea of the mouse after the onset of hearing. *Hear. Res.* 4, 89–102.

Lippe, W. and Rubel, E.W. (1983) Development of the place principle: tonotopic organization. *Science* 219, 514–516.

Lippe, W.R. (1987) Shift to tonotopic organization in brainstem auditory nuclei of the chicken during late embryonic development. *Hear. Res.* 2, 205–208.

Ostapoff, E.M. and Morest, D.K. (1989) A degenerative disorder of the central auditory system of the gerbil. *Hear. Res.* 37, 141–162.

Romand, R. (1987) Tonotopic evolution during development. *Hear. Res.* 28, 117–23.

Rubel, E.W. (1978) Ontogeny of structure and function in the vertebrate auditory system. In: M. Jacobson (Ed.), *Handbook of Sensory Physiology*. Springer-Verlag, New York, pp. 135–220.

Rubel, E.W., Smith, D.J. and Miller, I.C. (1976) Organization and development of the brain stem auditory nuclei of the chicken: Ontogeny of N. Magnocellularis and N. Laminaris. *J. Comp. Neurol.* 166, 469–490.

Rubel, E.W. and Ryals, B.M. (1983) Development of the place principle: acoustic trauma. *Science* 219, 512–514.

Ryan, A.F., Woolf, N.K. (1988) Development of tonotopic representation in the Mongolian gerbil: a 2-deoxyglucose study. *Brain Res.* 469, 61–70.

Ryals, B.M., Creech, H.B., Rubel, E.W. (1984) Postnatal changes in the size of the avian cochlear duct. *Acta Otolaryngol. (Stockh)* 98, 93–7.

Sanes, D.H., Merickel, M. and Rubel, E.W. (1989) Evidence for an alteration of the tonotopic map in the gerbil cochlea during development. *J. Comp. Neurol.* 279, 436–44.

Schmiedt, R.A. (1989) Spontaneous rates, thresholds and tuning of auditory-nerve fibers in the gerbil: comparisons to cat data. *Hear. Res.* 42, 23–35.

Schmiedt, R.A., Mills, J.H. and Adams, J.C. (1987) Effects of age and exposure to chronic noise on the physiology of the auditory periphery of the gerbil. *Abstr. Assoc. Res. Otolaryngol.* 10, 67.

Sher, A.E. (1971) The embryonic and postnatal development of

- the inner ear of the mouse. *Acta Oto-Laryngol. Suppl.* 285, 1-77.
- Woolf, N.J. and Ryan, A.F. (1984) The development of auditory function in the cochlea of the mongolian gerbil. *Hear. Res.* 13, 277-283.
- Yancey, C. and Dallos, P. (1985) Ontogenetic changes in cochlear characteristic frequency at a basal turn location as reflected in the summing potential. *Hear. Res.* 18, 189-196.
- Woolf, N.K. and Ryan, A.F. (1988) Contributions of the middle ear to the development of function in the cochlea. *Hear. Res.* 35, 131-142.
- Woolf, N.K., Ryan, A.F. and Harris, J.P. (1986) Development of mammalian endocochlear potential: normal ontogeny and effects of anoxia. *Am. J. Physiol.* 250 (3 Pt 2), R493-498.